



Parry-Romberg syndrome treatment with fat transfer and a new bleaching formula

Ioannis E. Liapakis MD, PhD¹  | Angelos C. Tzouganakis MD² |
 Eleftherios I. Paschalis PhD³  | Miriam Englander MD⁴ | Athanasios Christopoulos MD⁵ |
 Georgia Gloustanou MD⁶ | Paraskevas Kontoes MD, PhD^{7,8,9}

¹"OpsisClinical", Plastic and Reconstructive Surgery, Heraklion-Crete, Greece

²University of Crete School of Medicine, Heraklion-Crete, Greece

³Massachusetts Eye and Ear, Harvard Medical School, Boston, Massachusetts

⁴Ophthalmic Consultants of Boston, Boston, Massachusetts

⁵"Aesthetic Anaplasia", Cosmetic and Plastic Surgery, Athens, Greece

⁶"Histopathologic Diagnosis", Athens, Greece

⁷ISAPS, Athens, Greece

⁸DrK Medical Group, Athens, Greece

⁹Plastic, Aesthetic and Laser Surgery Department, HYGIEIA Hospital, Kifisia, Athens, Greece

Correspondence

Ioannis E. Liapakis, European Boards Certified Plastic Surgeon, Heraklion-Crete, Greece.
 Email: liapjo@yahoo.com

Summary

Parry-Romberg syndrome is a hemifacial atrophy which can be complicated by melasma. We present two cases of Parry-Romberg syndrome, treated by fat transfer and bleaching of the skin using a modified "Kligman's formula." The atrophy, as well as the skin dyschromia, improved, and the results were stable.

KEYWORDS

ascorbic acid, hemifacial atrophy, Kligman's formula, lipofilling, Parry-Romberg syndrome, skin hyperpigmentation

1 | INTRODUCTION

Parry-Romberg syndrome, with incidence of 1 / 700 000, is a progressive hemifacial atrophy of the skin and the subcutaneous tissue (Figure 1); in certain cases, muscles, cartilages, or bones may be involved.^{1,2} The syndrome is more commonly diagnosed in females in their early 20s and progresses over a 2-10 years period. However, sometimes it can be diagnosed as late as 40 or 60 years of age.^{1,3-6} It is characterized by thinning of the skin and the subcutaneous tissue and may be accompanied by hyperpigmentation, alopecia areata, hair color changes, involvement of the mimetic muscles underneath, and trigeminal neuralgia.^{4,5,7-12}

The treatment depends on the severity of the symptoms; for mild cases, fat/dermal grafts or fillers including hyaluronic acid and

calcium hydroxyapatite may be used.^{13,14} For more severe cases, intervention is delayed until symptoms are stable.¹⁴⁻¹⁶ Several invasive procedures have been proposed such as, free flap transfer, cantho-pexy, septo-rhinoplasty, or implantation of alloplastic materials.

In this study, we present the management of two Parry-Romberg syndrome cases using fat transfer and skin bleaching using a modified "Kligman's formula."

2 | MATERIALS AND METHODS

The first patient was a 21-year-old Caucasian female with left hemifacial atrophy. She was first diagnosed with Parry-Romberg syndrome at 17 years of age and was stable for at least 2 years prior to presentation. We treated her by transfer of 20 cc fat at the left forehead/nose/nasolabial crease/cheek and mental region. We first

None of the authors has any proprietary or financial interest on this study. This study was presented at the 6th Dermatologic Symposium "Attica", 21-23 January 2011, Athens, Greece

induced *Tumescent anesthesia* to minimize pain and bleeding at the anterior abdomen. We then used a multiple holes' cannula (1 mm diameter) with 10 cc luer lock syringes to harvest the fat. We centrifuged the fat at 3000 rpm for 3 minutes to separate the fat into three layers.^{17,18} The top and lower layer which contained destroyed adipocytes, oil, triglycerides, serum, and blood were removed and the refined fat of the middle layer was administered using a 1 cc syringe with a blunt tip cannula (in 1.7 mms diameter) to the area of deformity (Figure 2). Fat deposition was linear, in small portions per passage, in order to maximize cell survival (Figures 3 and 4). The skin hyperpigmentation was addressed using the modified "Kligman's formula" with 5% ascorbic acid.

The second patient was a 42-year-old Caucasian female with right hemifacial atrophy. She was first diagnosed at age of 39 years with continuous progression of the disease. She was treated by 80 cc of fat transfer to her right temporal region, cheek, lower eyelid, and nasolabial crease (Figures 5 and 6). The fat was harvested from the anterior abdomen under *Tumescent anesthesia* and centrifuged for

3 minutes at 3000 rpm and was administered to the right face using similar cannula (Figures 2 and 5). A second session of fat transfer of 50 cc was required to optimize the results. In addition, biopsies were taken from the atrophic area in both procedures to establish diagnosis.

3 | RESULTS

In the first patient, both the hemifacial atrophy and the skin hyperpigmentation remarkably improved with stable results for at least 6 months postop (Figure 4).

In the second patient (Figure 7), two fat transfer sessions were needed but no skin bleaching treatment was required. Interestingly, in the pathology report there was no evidence of atrophy of the dermis and subcutaneous fat, but there was evidence of epidermal atrophy, papillary dermal fibrosis, and mild peri-adnexal, with lymphocytic-perivascular infiltration (Figure 8). Biopsies were taken 12 months after the last fat transfer to establish the diagnosis (Figure 9). Histopathologic findings showed that the epidermal atrophy was stable, as well as the mild atrophy/paucity of the appendageal structures. In addition, the findings included thickening of the collagen bundles, mild peri-adnexal with lymphocytic-perivascular dermal infiltration, and impressive thickening of the trabeculae subdividing of the subcutaneous fat (probably due to the lipofiling). To our knowledge, this is the first histopathological report of a Parry-Romberg syndrome patient.

4 | DISCUSSION

Parry-Romberg syndrome is typically a superficial condition however, muscle or bony involvement with eye and trigeminal nerve complications have been reported.¹⁹ Surgical reconstruction is often required^{20,21} to help skeleton and ocular growth¹³⁻¹⁶ once the symptoms are stable.²² Fat transfer, dermal grafts, and *medpore*/silicone implants can be used with free flaps, canthoplasty, or rhinoplasty in more complicated cases.

Currently, liposuction and lipofiling are the "gold standard" for the treatment of Parry-Romberg syndrome.^{23,24} Liposuction was first described by *Illouz*²⁵ and then was popularized by *Klein* with "Tumescent" anesthesia.²⁶ However, *Coleman*²⁷ introduced lipofiling technique with gentle liposuction and centrifugation of the fat, thereby increasing the survival rate of the transferred fat cells.²⁸




FIGURE 1 "Fayum" probably with Parry-Romberg syndrome from 70bC at Egypt




FIGURE 2 Cannulas used for liposuction (upper) and lipofiling (lower) to the face

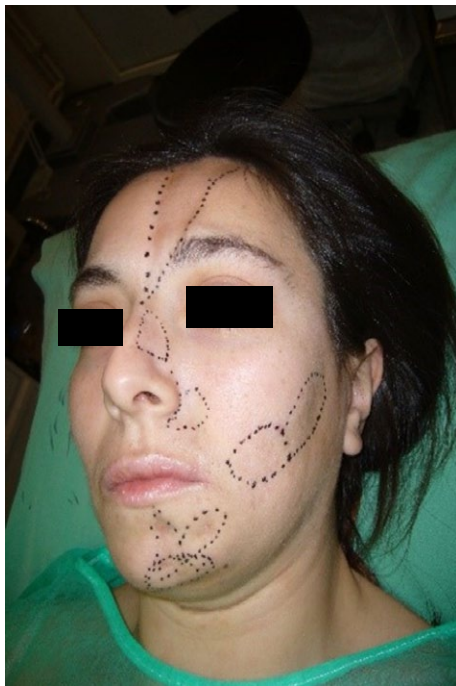

FIGURE 3 Intraoperative photo of the treated areas. Written informed consent was obtained from the participant for publication of this case report and any accompanying images

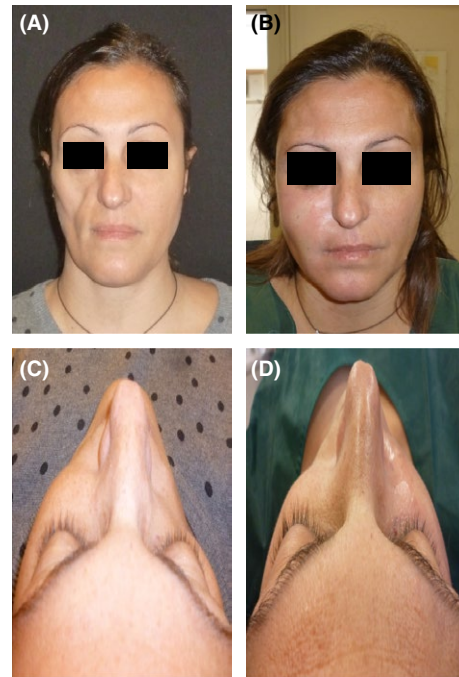


FIGURE 5 Patient with Parry-Romberg syndrome of her right face (A) with loss of projection before (C) and immediately after (B, D) the 1st session of 80 cc of fat transfer to her right face. Written informed consent was obtained from the participant for publication of this case report and any accompanying images

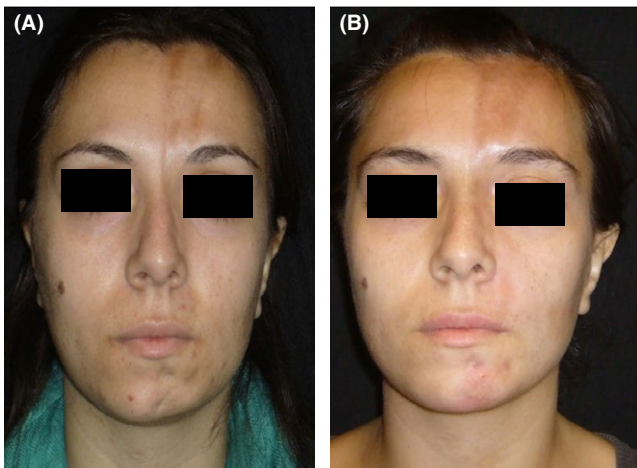


FIGURE 4 Same patient with Parry-Romberg syndrome before (A) and 6 mo (B) after treatment

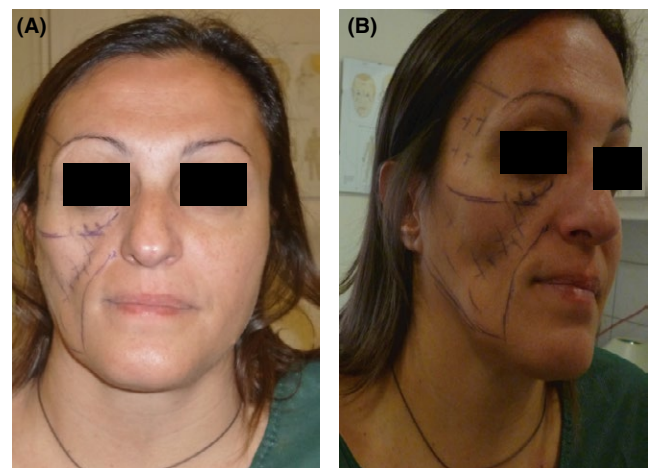

FIGURE 6 Markings (A, B) for the second patient before fat transfer

Previous reports have shown only 40%-70% of fat cells survive when transferred to the face.²⁹ In order to further improve fat cells survival, *Matsumoto*³⁰ and *Yoshimura*³¹ enriched aspirated fat cells with adipose-derived stem cells (ASCs), and described adipose tissue regeneration and angiogenesis.

In our study, we performed liposuction of the anterior abdomen wall, we centrifuged the fat, and isolated the middle layer containing pure fat cells for subsequent lipofiling. The top and bottom layers were discarded. Purified fat was transferred in both cases with

repeated injections. In order to prevent severe complications, we took special care to ensure that the injections were as atraumatic as possible. Hence, a cannula with diameter larger than the recipient vessels was used blindness after filler induction around the nose, forehead, and temporal region.³² The patients were followed for at least 6 months after lipofiling, which is adequate to assess fat survival.³³

We also added 5% vitamin C to the original "Kligman's formula" in order to manage skin hyperpigmentation. "Kligman's formula" is

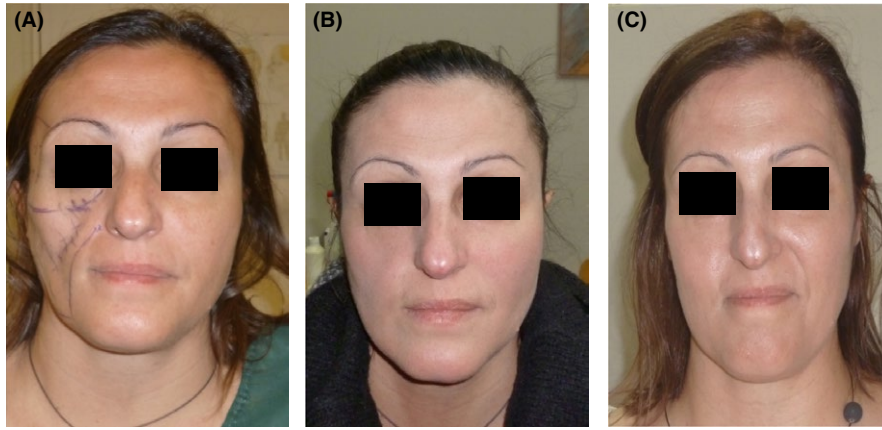

FIGURE 7 Patient pre-(A), 3 mo (B) after the 1st session and 12 mo (C) after the 2d session

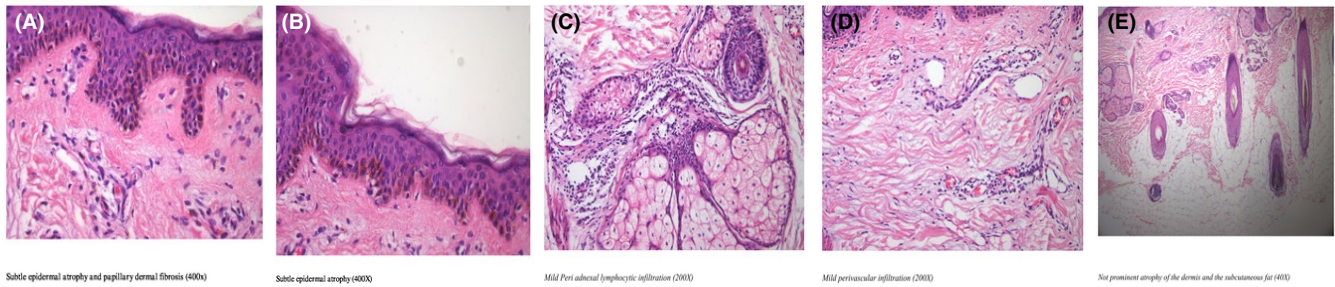


FIGURE 8 Histopathology of the biopsies of the 2nd Parry-Romberg patient before lipofiling. A, Subtle epidermal atrophy and papillary dermal fibrosis (400X). B, Subtle epidermal atrophy (400X). (C) Mild peri-adnexal lymphocytic infiltration (200X). D, Mild perivascular infiltration (200X). E, No prominent atrophy of the dermis and subcutaneous fat (40X)

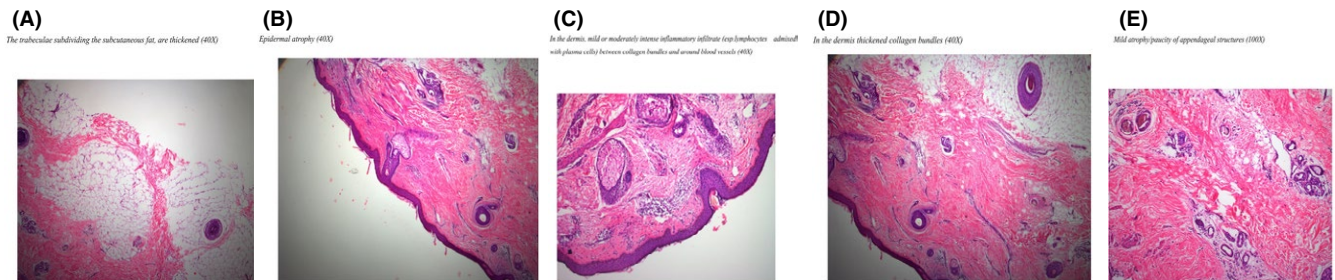


FIGURE 9 Histopathology of the biopsies of the 2nd Parry-Romberg patient after lipofiling. A, The trabeculae subdividing the subcutaneous fat are thickened (40X). B, Epidermal atrophy (40X). C, In the dermis, mild or moderately intense inflammatory infiltrate (esp. lymphocytes admixed with plasma cells) between collagen bundles and around blood vessels (40X). D, In the dermis thickened collagen bundles (40X). E, Mild atrophy/paucity of appendageal structures (100X)

the gold standard for the treatment of melasma. It contains hydroquinone 5%, tretinoin 0.1%, and dexamethasone 0.1%.³⁴ It has been extensively used for the treatment of postinflammatory hyperpigmentation (PIH), chloasma, age spots, scars, and nevi of Ota or Hori alone or with laser therapy³⁵⁻³⁷. Hydroquinone inhibits the conversion of dopa to melanin. Jimbow *et al.* proved that it degrades melanosomes and destroys melanocytes.³⁸ Although there are no known risks, allergic reactions and ochronosis-like pigmentation have been reported.³⁹

The disorder is characterized by progressive darkening of the skin and degeneration of collagen and elastic fibers. The

degeneration is followed by ochronotic deposits consisting of crescent-shaped, ocher-colored fibers in the dermis. The condition is difficult to treat, but it can respond to topical steroids, bimatoprost treatment, and peeling. Other whitening agents like kojic acid and azelaic acid⁴⁰ are not as effective as hydroquinone and may cause complications (Table 1). *Er:YAG* and *Q-switch*³⁴ lasers can provide short term improvement however, they may cause prolonged erythema which requires in average 6 months to resolve.

Tretinoin inhibits tyrosinase transcription, increases proliferation of keratinocytes, and interrupts melanin synthesis⁴¹ but may

TABLE 1 Bleaching agents used for the treatment of hyperpigmentation and possible complications

Bleaching agents	Complications
Azelaic acid with 0.05% tretinoin (38)	No complications
Azelaic acid with 15%-20% glycolic acid (38)	No complications
Kojic acid 2% in combination with hydroquinone 2%	No complications
Glycolic acid 10% with hydroquinone 2% (39)	No complications
"Kligman's formula" (hydroquinone 4% with tretinoin 0.1% and dexamethasone 1% in a hydrophilic ointment)	Allergic reactions, contact dermatitis, nail bleaching, and ochronosis-like pigmentation
Tretinoin 0.05%-0.1% (53)	Erythema or increase the pigmentation due to skin irritation
Ascorbic acid	No complications

cause erythema and skin irritation as well.⁴² It has to be combined with hydroquinone to improve skin penetration. The addition of hydrocortisone to the formula eliminates skin irritation and decreases melanin synthesis.^{43,44} However, the use of hydrocortisone should be limited to 3-4 months to prevent skin atrophy, telangiectasia, and extreme sensitivity to sun exposure.

Vitamin C (L-ascorbic acid) increases the bleaching activity of the formula as it blocks the oxidative chain reaction from tyrosine/dihydroxyphenylalanine (DOPA) to melanin⁴⁵ and stimulates collagen synthesis.⁴⁶

In our study, the modified formula was gradually applied to minimize skin irritation for 1-month period. During the first week, it was applied for 1 hour on the skin. On the, second week it was applied for 2 hours, on the third week for 3 hours, and on the fourth week for overnight. Hydration and sun care cream were used for moisturization and sun protection. Strict sun avoidance along with broad-spectrum sunscreen were recommended to prevent relapse. The proposed bleaching treatment required 3-4 months for stable results.⁴³

5 | CONCLUSION

Lipofiling and bleaching of the skin with the proposed modified *Kligman's formula* significantly improves Parry-Romberg syndrome. However, more studies are needed to establish the safety and efficacy of the results.

ORCID

Ioannis E. Liapakis  <http://orcid.org/0000-0001-7568-2323>

Eleftherios I. Paschalis  <https://orcid.org/0000-0002-4544-4452>

REFERENCES

- Mazzeo N, Fisher JG, Mayer MH, Mathieu GP. Progressive hemifacial atrophy (Parry-Romberg syndrome). Case report. *Oral Surg Oral Med Oral Pathol Oral Radiol Endod.* 1995;79:30-35.
- Miedziak AI, Stefanyszyn M, Flanagan J, Eagle Jr RC. Parry-Romberg syndrome associated with intracranial vascular malformations. *Arch Ophthalmol.* 1998;116:1235-1237.
- Terenzi V, Leonardi A, Covelli E, et al. Parry Romberg syndrome. *Plast Reconstr Surg.* 2005;116(5):97e-102e.
- Iñigo F, Jimenez-Murat Y, Arroyo O, Fernandez M, Ysunza A. Restoration of facial contour in Romberg's disease and hemifacial microsomia: experience with 118 cases. *Microsurgery.* 2000;M20:167-172.
- El-Kehdy J, Abbas O, Rubeiz N. A review of Parry-Romberg syndrome. *J Am Acad Dermatol.* 2012;67:769-784.
- Duymaz A, Karabekmez FE, Keskin M, Tosun Z. Parry-Romberg syndrome: facial atrophy and its relationship with other regions of the body. *Ann Plast Surg.* 2009;63:457-461.
- Longo D, Paonessa A, Specchio N, et al. Parry-Romberg syndrome and Rasmussen encephalitis: possible association. Clinical and neuroimaging features. *J Neuroimaging.* 2011;21(2):188-193.
- Drummond PD, Hassard S, Finch PM. Trigeminal neuralgia, migraine and sympathetic hyperactivity in a patient with Parry-Romberg syndrome. *Cephalalgia.* 2006;26:1146-1149.
- Aynaci FM, Sen Y, Erdöl H, Ahmetoğlu A, Elmas R. Parry-Romberg syndrome associated with Adie's pupil and radiologic findings. *Pediatr Neurol.* 2001;25:416-418.
- Ho LC. Refinements in rejuvenative facial lipomorphoplasty. *Aesth Plast Surg.* 2002;26:329-334.
- Yano T, Sawaishi Y, Toyono M, Takaku I, Takada G. Progressive facial hemiatrophy after epileptic seizures. *Pediatr Neurol.* 2000;23:164-166.
- Stone J. Parry-Romberg syndrome: a global survey of 205 patients using the Internet. *Neurology.* 2003;61(5):674-676.
- Jun JH, Kim HY, Jung HJ, et al. Parry-Romberg syndrome with en coup de sabre. *Ann Dermatol.* 2011;23:342-347.
- Baek R, Heo C, Kim B-K. Use of various free flaps in progressive hemifacial atrophy. *J Craniofac Surg.* 2011;22:2268-2271.
- Cox SE, Soderberg JM. Idiopathic hemifacial atrophy treated with serial injections of calcium hydroxylapatite. *Dermatol Surg.* 2010;36(4):542-545.
- Agostini T, Spinelli G, Marino G, Perello R. Esthetic restoration in progressive hemifacial atrophy (Romberg Disease): structural fat grafting versus local/free flaps. *J Craniofac Surg.* 2014;25:783-787.
- Cervelli V, Gentile P. Use of cell fat mixed with platelet gel in progressive hemifacial atrophy. *Aesth Plast Surg.* 2009;33:22-27.
- Bui P. Complications of autografting. *Ann Chir Plast Esthet.* 2004;49:630-636.
- Gorlin R, Cohen N, Hennekam R. *Syndromes with unusual facies: Well-Known Syndromes. Syndromes of the Head and Neck*, 4th edn. New York, NY: Oxford University Press; 2001:977-1038.

20. Si L, Zeng A, Qiao Q, et al. Microsurgical correction of progressive facial hemiatrophy using free anterolateral thigh adipofascial flap. *J Craniofac Surg*. 2012;23(7Suppl 1): 2051–2056.
21. Tanna N, Broer PN, Roostaeian J, Bradley JP, Levine JP, Saadeh PB. Soft tissue correction of craniofacial microsomia and progressive hemifacial atrophy. *J Craniofac Surg*. 2012;23:2024–2027.
22. Slack GC, Tabit CJ, Allam KA, Kawamoto HK, Bradley JP. Parry-Romberg reconstruction: optimal timing for hard and soft tissue procedures. *J Craniofac Surg*. 2012;23(7 Suppl 1):1969–1973.
23. Guerrerosantos J, Guerrerosantos F, Orozco J. Classification and treatment of facial tissue atrophy in Parry-Romberg disease. *Aesthetic Plast Surg*. 2007;31:424–434.
24. Castro-Govea Y, De LaGarza-Pineda O, Lara-Arias J, et al. Cell-assisted lipotransfer for the treatment of Parry-Romberg syndrome. *Arch Plast Surg*. 2012;39(6):659–662.
25. Illouz YG. Surgical remodeling of the silhouette by aspiration lipolysis or selective lipectomy. *Aesthetic Plast Surg*. 1985;9:7–21.
26. Klein JA. Tumescent technique for regional anesthesia permits lidocaine doses of 35 mg/kg for liposuction. *J Dermatol Surg Oncol*. 1990;16(3):248–263.
27. Coleman SR. Facial recontouring with lipostructure. *Clin Plast Surg*. 1997;24:347–367.
28. Clauser LC, Tieghi R, Consorti G. Parry-Romberg syndrome: volumetric regeneration by structural fat grafting technique. *J CrMax Fac Surg*. 2010;38:605–609.
29. Mojallal A, Shipkov C, Braye F, Breton P, Foyatier JL. Influence of the recipient site on the outcomes of fat grafting in facial reconstructive surgery. *Plast Reconstr Surg*. 2009;124:471–483.
30. Matsumoto D, Sato K, Gonda K, et al. Cell-assisted lipotransfer: supportive use of human adipose-derived cells for soft tissue augmentation with lipoinjection. *Tissue Eng*. 2006;12:3375–3382.
31. Yoshimura K, Sato K, Aoi N, et al. Cell-assisted lipotransfer for facial lipoatrophy: efficacy of clinical use of adipose-derived stem cells. *Dermatol Surg*. 2008;34:1178–1185.
32. Beleznyay K, Carruthers JD, Humphrey S, Jones D. Avoiding and treating blindness from fillers: a review of the world literature. *Dermatol Surg*. 2015;41(10):1097–1117.
33. Illouz YG, Sterodimas A. Autologous fat transplantation to the breast: a personal technique with 25 years of experience. *Aesthetic Plast Surg*. 2009;33(5):706–715.
34. Momosawa A, Kurita M, Ozaki M, et al. Combined therapy using Q-switched ruby laser and bleaching treatment with tretinoin and hydroquinone for periorbital skin hyperpigmentation in Asians. *Plast Reconstr Surg*. 2008;121(1):282–288.
35. Kligman AM, Willis I. A new formula for depigmenting human skin. *Arch Dermatol*. 1975;111(1):40–48.
36. Siadat AH, Iraj F, Bahrami R, et al. The comparison between modified Kligman formulation versus Kligman formulation and intense pulsed light in the treatment of the post-burn hyperpigmentation. *Adv Biomed Res*. 2016;5:125.
37. Majid I. Mometasone-based triple combination therapy in melasma: is it really safe? *Indian J Dermatol*. 2010;55(4):359–362.
38. Jimbow K, Obata H, Pathak MA, Fitzpatrick TB. Mechanism of depigmentation by hydroquinone. *J Invest Dermatol*. 1974;62(4):436–449.
39. Barrientos N, Ortiz-Frutos J, Gomez E, Iglesias L. Allergic contact dermatitis from a bleaching cream. *Am J Contact Derm*. 2001;12(1):33–34.
40. Haddad AL, Matos LF, Brunstein F, Ferreira LM, Silva A, Costa Jr D. A clinical, prospective, randomized, double-blind trial comparing skin whitening complex with hydroquinone vs. placebo in the treatment of melasma. *Int J Dermatol*. 2003;42(2):153–156.
41. Tagliolatto S, Santos Neto Ode O, Alchorne MM, Enokihara MY. Sebaceous hyperplasia: systemic treatment with isotretinoin. *An Bras Dermatol*. 2015;90(2):211–215.
42. Mahé A, Ly F, Perret JL. Systemic complications of the cosmetic use of skin-bleaching products. *Int J Dermatol*. 2005;44(Suppl 1):37–38.
43. Perez-Bernal A, Munol-Perez MA, Camacho F. Management of facial hyperpigmentation. *Am J Clin Dermatol*. 2000;1:261–268.
44. Draelos ZD. A split-face evaluation of a novel pigment-lightening agent compared with no treatment and hydroquinone. *J Am Acad Dermatol*. 2015;72(1):105–107.
45. Espinal-Perez LE, Moncada B, Castanedo-Cazares JP. A double blind randomized trial of 5% ascorbic acid versus 4% hydroquinone in melasma. *Int J Dermatol*. 2004;43:604–607.
46. Wagner AE, Rimbach G. Ascorbigen: chemistry, occurrence and biological properties. *Clin Dermatol*. 2009;27(2):217–224.

How to cite this article: Liapakis IE, Tzouganakis AC, Paschalis EI, et al. Parry-Romberg syndrome treatment with fat transfer and a new bleaching formula. *J Cosmet Dermatol*. 2019;00:1–6. <https://doi.org/10.1111/jocd.12819>